

## Non-Surgical Endodontic Therapy as Treatment of Choice for a Misdiagnosed Recurring Extraoral Sinus Tract

Frederik CURVERS, Petra DE HAES, Paul LAMBRECHTS

### ABSTRACT

The purpose of this article is to present the treatment of an odontogenic cutaneous sinus tract with exuberant extraoral granulation tissue and its successful endodontic treatment and follow up with Cone-Beam Computed Tomography (CBCT). In this case, a 31-year-old woman was referred for management of a reddish nodule on her chin. Previous surgical and antibiotic intervention by the dermatologist had not resolved the problem. Profound clinical and radiological examination (including CBCT) revealed apical periodontitis of tooth 32 to be the cause of the recurring cutaneous sinus tract. Conservative non-surgical root canal treatment was performed. With the aid of a topical corticosteroid and supplemental antibiotic therapy, healing of the apical periodontitis and resolution of the granulation tissue was evident after 1 year both clinically and radiographically. This case report emphasises the need for more awareness by dermatologists and other medical practitioners for the differential diagnosis of extraoral sinus tracts. Correct diagnosis of the dental cause can prevent unnecessary and multiple antibiotic and surgical interventions. Antibiotic therapy should never be administered without addressing the underlying dental cause. Conservative non-surgical endodontic treatment is the treatment of choice for an extraoral sinus tract of endodontic origin.

**Keywords:** Apical periodontitis, cone-beam computed tomography, sinus tract

### HIGHLIGHTS

- More awareness should be given by dermatologists and other medical practitioners to the differential diagnosis of extraoral sinus tracts, reminding the possibility of a dental origin.
- Correct diagnosis and treatment of the dental cause of an extraoral sinus tract can prevent unnecessary and multiple antibiotic and surgical interventions.
- Conservative non-surgical endodontic treatment is the treatment of choice for an extraoral sinus tract of endodontic origin and should always be attempted first.

### INTRODUCTION

Apical periodontitis is an inflammatory disease that may take an acute, subacute, or chronic course. Chronic apical periodontitis may present as a dental granuloma or a periradicular cyst and is characterised by the development of connective tissue and by the factors of destruction and repair (1). The most common initiating factor for an acute periradicular abscess is carious exposure and subsequent bacterial invasion of the tooth pulp. In some cases, the chronic presence of inflammation can give rise to a sinus tract. This sinus tract can find its way to the oral cavity or, less frequently, the cutaneous extraoral surface (2). The infection will follow the path of least resistance when exiting from the root apex area and travelling through bone and soft

tissue. Once the cortical plate has been perforated, the sinus tract's exit point is determined by the location of muscle attachments and fascial sheaths, the position of the tooth in the dental arch, the thickness of the bone, and the distance until it reaches the intra- or extraoral environment (3). Also, factors such as gravity and the virulence of the microorganisms involved play a role.

A cutaneous sinus tract of dental origin is relatively uncommon and may be easily misdiagnosed because of its rare occurrence and the absence of dental symptoms (4). Although it is a well-known

Please cite this article as: Curvers F, De Haes P, Lambrechts P. Nonsurgical endodontic therapy as treatment of choice for a misdiagnosed recurring extraoral sinus tract. *Eur Endod J* (2017) 2:13.

From the Department of Oral Health Sciences (F.C. ✉ Frederik.Curvers@kuleuven.be, P.L.), University of Leuven, University Hospitals Leuven, Leuven, Belgium; Department of Dermatology (P.D.H.), University of Leuven, University Hospitals Leuven, Leuven, Belgium.

Received 27 January 2017, revision requested 27 February 2017, last revision received 1 April 2017, accepted 10 April 2017.

Published online: 15 June 2017  
DOI 10.5152/eej.2017.17007

complication, these lesions continue to be a diagnostic dilemma because most patients usually seek treatment from a physician or a surgeon rather than from a dentist (5). Many patients receive multiple antibiotic regimens and undergo multiple surgical sessions but still suffer recurrence of the sinus tract because the primary dental aetiology was never correctly diagnosed (6). Not recognising the dental origin often leads to destructive treatments that can be mutilating and will never be curative. Even a skin biopsy may produce unnecessary scarring (5). This extraoral draining sinus typically presents itself as an erythematous, smooth, non-tender nodule with crusting. Periodical drainage of pus occurs in some cases. Dimpling or retraction below the normal skin surface is characteristic. Frequently a cord-like tract attaching to the underlying alveolar bone in the area of the suspected tooth can be palpated.

The purpose of this article is to present a rare case of a cutaneous sinus tract with an exuberant granulation tissue and its resolution after successful endodontic treatment, including a follow up with cone-beam computed tomography (CBCT).

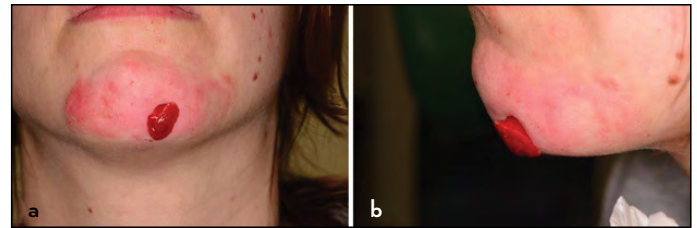
### CASE PRESENTATION

A healthy 31-year-old woman visited the department of oral health sciences of the university hospital in Leuven for a second opinion. The main complaint was a shiny smooth nodule on her chin that had been present for almost a year (Figure 1a, b). The patient experienced no pain, and there were no details worth mentioning in the medical history of the patient; she took no medication and had no allergies. Previous surgical intervention by a dermatologist had not resolved the problem. Based on the histological examination of an earlier lesion removed by the dermatologist, the diagnosis of exuberant granulation tissue was made (Figure 2a, b).

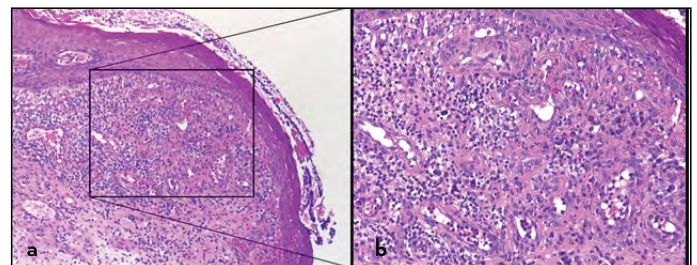
During extraoral inspection, a red lobulated exophytic lesion could be seen at the left of her chin (Figure 3a). Since the beginning, the patient wore a bandage over the lesion for aesthetic reasons, and this had caused an allergic irritation of the surrounding skin. The nodule bled easily upon palpation, it was compressible, and it had a sessile base (Video 00:00-00:48, See Page: <https://doi.org/10.5152/eej.2017.17007>). Closer examination using the dental microscope (Opmi Pico, Carl Zeiss, Oberkochen, Germany) revealed a highly vascular tissue of approximately 0.8 inches in width (Figure 3b).

Clinical intra-oral examination revealed poor dental hygiene. All teeth, except tooth 32, reacted positively to cold testing with carbon dioxide snow. None of the teeth were tender to percussion. Pocket depths of 5 mm were probed around tooth 32, but no pocket reached the apex. Periapical radiography showed a periapical lesion associated with tooth 32 (Figure 4a). The patient could remember a trauma in her childhood where she fell on the mandibular front teeth. Palpation of the M. mentalis revealed firm muscle tension accompanied with strong lip pressure. A CBCT scan (3D Accuitomo® 170, J. Morita MFG Corp,

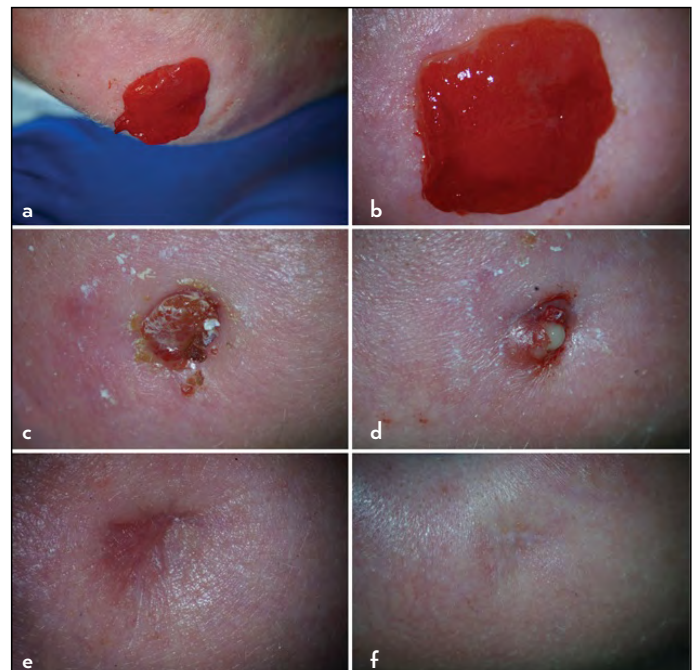
Kyoto, Japan) was acquired to assess the extensiveness of the lesion in three dimensions (Figure 5a-c). The scanning parameters were 90kVp, 5 mA, a spatial resolution of 160 µm and a field-of-view of 80x80 mm. Information about the anatomy of the root, the dimensions of the lesion and the relation with the surrounding tissues was visualised. Cortical expansion of the bone with discrete vestibular disruption was seen.



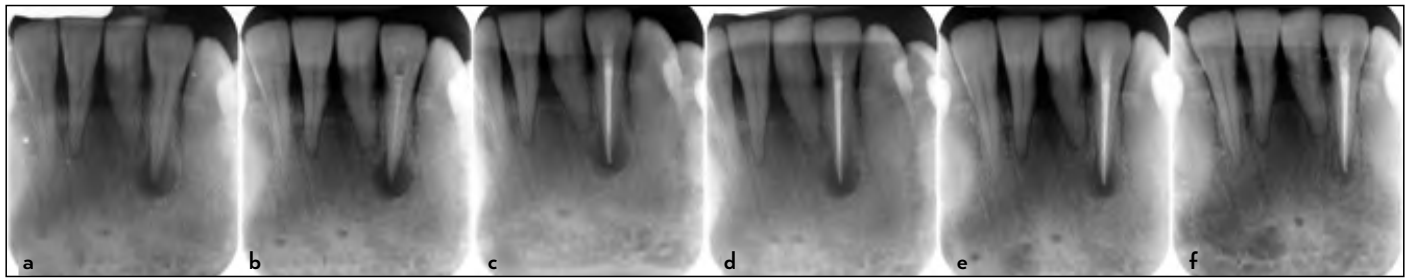**Figure 1.** a, b. Clinical appearance before treatment, (a) frontal view of the patient at intake, note the irritative dermatitis, (b) sagittal view showing the sessile base of the red nodule



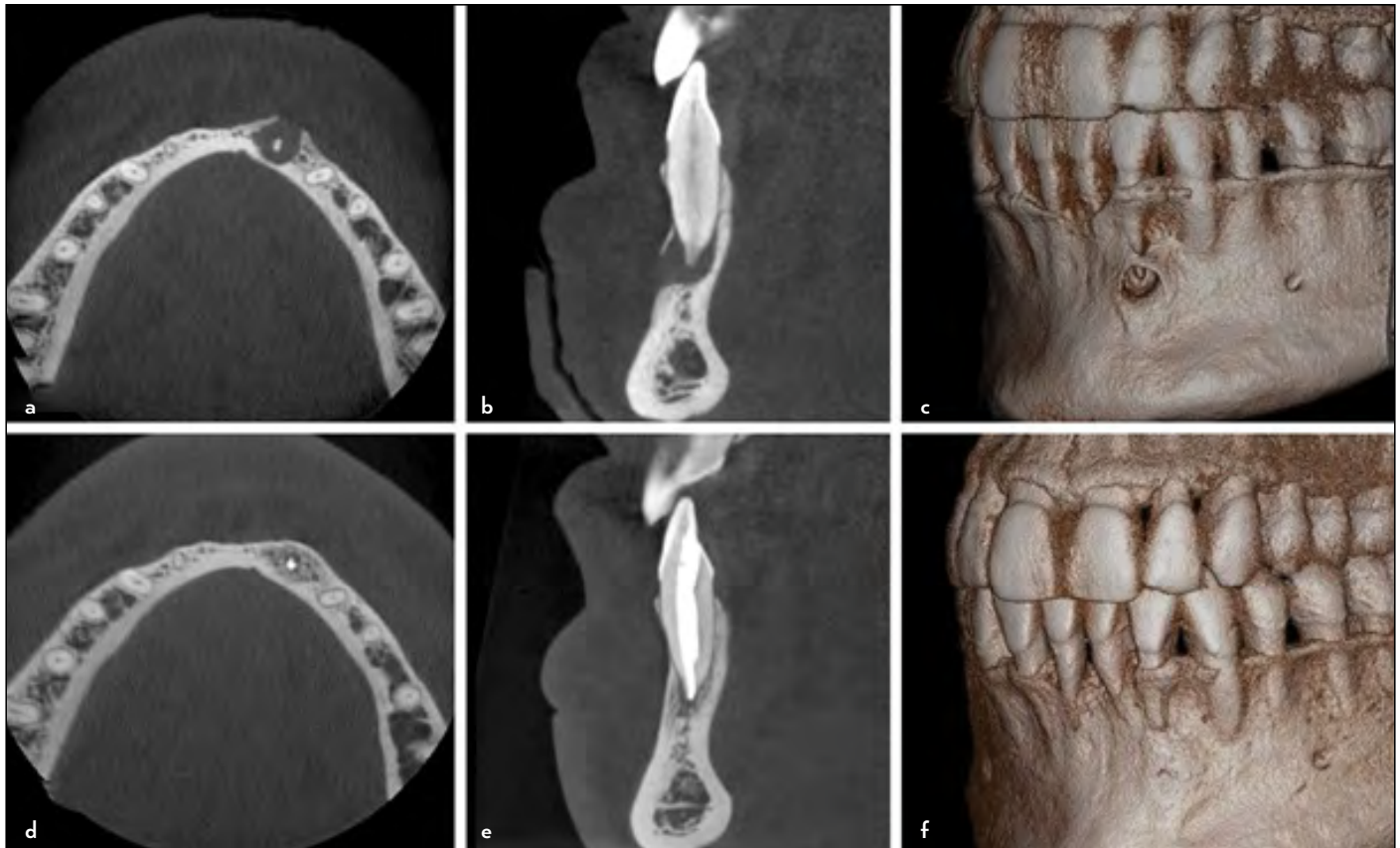
**Figure 2.** a, b. Histological findings of the removed lesion by the dermatologist showing granulation tissue. (a) Overview, (b) higher magnification showing several blood vessels embedded in a loose connective tissue containing fibroblasts and inflammatory cells (Haematoxylin and eosin stain)



**Figure 3.** a-f. Clinical changes of the granulation tissue, (a) at intake, (b) detail of the granulation tissue, (c) endodontic treatment and a corticosteroid ointment made the granulation tissue shrink, (d) some purulent exudate was still visible 3 months after endodontic treatment, and an antibiotic treatment was prescribed, (e) clinical picture 10 days after the use of antibiotics, (f) after 1 year, a small discrete scar remained



**Figure 4. a-f.** Periapical radiographs showing the changes of the granuloma. (a) At intake, periapical radiolucency was visible, (b) Ca(OH)<sub>2</sub> paste as an interappointment dressing, (c) endodontic treatment, (d) three months follow up showed no signs of healing, (e) six months follow up showed ongoing bone healing, (f) one year follow up showed healing of the periapical tissues



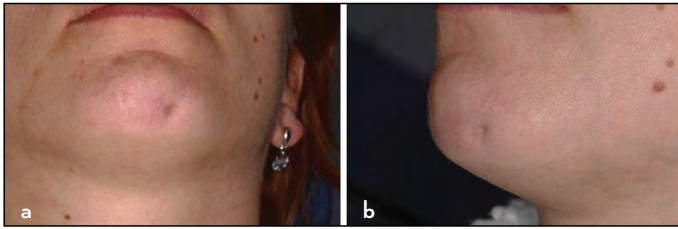**Figure 5. a-f.** CBCT findings, (a) cross-sectional image showing destruction and expansion of the cortical bone, (b) sagittal image of tooth 32, (c) three-dimensional reconstruction, Note the root tip of tooth 32 through the destroyed bone, (d) cross-sectional image one year after endodontic treatment showing a closed cortex and new trabecular bone around the root tip, (e) sagittal image after endodontic treatment, (f) three-dimensional reconstruction showed healing of the cortical bone

CBCT: cone-beam computed tomography

The final diagnosis was made of an odontogenic cutaneous sinus tract with exuberant granulation tissue secondary to a necrotic pulp with asymptomatic apical periodontitis of tooth 32. The tooth was endodontically treated following the quality guidelines for endodontic treatment as described in the consensus report of the European Society of Endodontology (Figure 4b, c) (7).

A betamethasonevalerate 0.1%-based ointment in combination with zinc oxide 10% was prescribed to apply twice a day onto the red nodule for a period of 10 days. Professional periodontal treatment was conducted afterwards. One

month later, the granulation tissue was reduced in size (Figure 3c). The ointment with zinc oxide 10% but without the corticosteroid was continued for another 4 weeks. Two months later, the formation of scar tissue could be seen at the borders of the lesion. Three months later, periapical radiography showed no clear signs of healing (Figure 4d), a purulent exudate was visible (Figure 3d) and the sinus tract could still be explored with a gutta percha cone (Video 00:49-00:58, See Page: <https://doi.org/10.5152/eej.2017.17007>). Because of the remaining purulent exudate, a microbiological sample was taken from the sinus tract for bacterial identification. *Actinomyces oris*, *Streptococcus sanguinis* and *Porphyromonas*



**Figure 6. a, b.** Clinical appearance after treatment, (a) frontal view of the patient, only a discrete scar remained 1 year after treatment, (b) sagittal view 1 year after treatment

*gingivalis* were identified. A supplementary antibiotic treatment with amoxicillin (875 mg) and clavulanic acid (125 mg) (Augmentin®) combined with metronidazole for 10 days was started. One month after the antibiotic therapy and 4 months after initial therapy, the extraoral granuloma had completely disappeared. Only a small scar at the left of her chin could be noticed (Figure 3e). The original connecting fibrous tissue cord inside the chin could still be palpated.

Periapical radiography showed ongoing healing after 6 months and full healing after 1 year (Figure 4e, f). Because the patient was part of an ongoing randomised controlled clinical trial (NCT02528240, approved by the Ethics Committee of UZ Leuven) comparing periapical healing of non-surgical endodontic treatment versus endodontic microsurgery using CBCT, a follow up CBCT was taken to evaluate the bone healing. Bone healing could be seen in all three dimensions, and the cortical disruption was closed (Figure 5d-f). Extraoral inspection revealed the presence of a discrete scar (Figure 3f) (Video 00:59-01:30, See Page: <https://doi.org/10.5152/ej.2017.17007>). However, the patient had no complaints and was satisfied with the healing so no further aesthetic treatments were planned (Figure 6a, b).

## DISCUSSION

An odontogenic cutaneous sinus tract is a pathologic channel that originates in the oral cavity but exits at the cutaneous surface of the face or neck. It commonly resembles a furuncle, a cyst, or an ulcer, or it looks like a retracted or sunken skin lesion (3, 8). In this case, the dental origin of the extraoral sinus tract was initially not recognised. It was previously misdiagnosed as a lobular capillary haemangioma (LCH). However, the histological examination did not show the typical characteristics of LCH (Figure 2a, b). There were no signs of lobulated proliferation of capillary vessels and no clear signs of an attenuated surface epithelium with an epidermal collarette at the margin formed by elongated rete ridges. This lobular arrangement of the lesions is distinct from the pattern of capillaries in granulation tissue, and unlike granulation tissue the capillaries do not usually involute with time (9).

Except in people with a compromised immune system, antibiotics (AB) are not curative but function to assist in the re-establishment of the proper balance between host defence and the

invasive agents. The indications for adjunctive AB following the American Association of Endodontists are fever, malaise, lymphadenopathy, trismus, increased swelling, cellulitis, osteomyelitis and persistent infection (10). After 3 months, there was a purulent exudate from the fistula. Microbial culturing of the pus revealed the presence of three dominant species *Actinomyces oris*, *Streptococcus sanguinis* and *Porphyromonas gingivalis*. In case of persistent infection, the use of AB can be indicated, supplemental to endodontic therapy (10). Bacteria can shelter in the periradicular tissues either by adhering to the apical external root surface or as an independent colony in the inflammatory lesion. *Actinomyces* species are known to form cohesive actinomycotic colonies and maintain infection. Once the intraradicular infection is properly controlled by root canal treatment, supplemental antibiotic therapy can aid the immune system in handling the extraradicular infection. This was sufficient in this case, but sometimes periapical surgery is needed (11). The administering of AB does not always guarantee healing of a persistent endodontic infection. Removal of the apical lesion by endodontic microsurgery is a viable and established treatment option. Penicillin's are the AB of choice for endodontic infections (12). Because of the microbial culturing, both Augmentin® and metronidazole were prescribed and gave resolution of the extraoral granuloma in 3 days. *Porphyromonas gingivalis* is a non-fermentative black-pigmented gram-negative, obligate anaerobic rod and is well known as a periopathogen. *Porphyromonas gingivalis* has been associated with symptomatic periradicular lesions, including abscessed teeth (13, 14) and may be involved in the induction of acute periapical lesions and the sometimes long-standing fistulae associated with periapical infections refractory to conventional therapy (15). In a study of Jacinto et al. (14), the presence of *Porphyromonas gingivalis* was related to purulent exudates and pain on palpation. All the *Porphyromonas gingivalis* strains tested in their study were sensitive to metronidazole in vitro. It is well established that *Porphyromonas gingivalis* is not sensitive to  $\text{Ca}(\text{OH})_2$  (16).

Betamethasonevalerate is a class III topical corticosteroid that suppresses inflammation. Together with zinc oxide, it gives a local drying and suppressive effect (17). In our case, the corticosteroid cream was stopped after 10 days, but the zinc oxide was continued for another 4 weeks (18).

Extraoral sinus tracts are frequently associated with mandibular teeth. In the literature, they have been documented in 80-87% of the cases in the lower jaw (19). In our case, the origin could be found at a mandibular incisor. The sinus tract ended at the chin of the patient. From an anatomical point of view, this can be explained by the muscle attachments. When the infection spreads inferior to the mentalis muscle attachment, it can reach the skin (20). The diagnosis of these sinus tracts is not an easy task due to the absence of symptoms and the distance between origin and lesion. Tracking the sinus tract with a gutta percha cone contributes to the correct diagnosis (21). A lot of diseases have similar symptoms making the differen-

tial diagnosis more difficult. A good differentiation with traumatic lesions, salivary gland and duct fistula, basal cell carcinoma, osteomyelitis, lobular capillary haemangioma, foreign bodies, congenital fistula and local skin infections (as inflamed epidermoid cyst and folliculitis) should be made (7, 20).

Only two cases of extraoral sinus tracts where CBCT was used to help in the diagnosis were found in the literature (22, 23). Some authors used CT to visualise the path of the sinus in the soft tissues, but only Tian et al. (23) used CBCT in the follow up of this pathology (24, 25).

The treatment options for an extraoral sinus tract are non-surgical root canal treatment, apical surgery, or extraction. As suggested in the literature, non-surgical root canal treatment is the treatment of choice and should always be attempted first (26). In most cases, the sinus tract heals successfully with minimal scar tissue (21, 26). In a study by Bodner et al. (27), the cosmetic result after treatment was satisfying in 70% of the 28 cases treated. The need for scar revision will increase the longer the sinus tract is present. Slight dimpling and hyperpigmentation of the area is not uncommon, and this usually diminishes with time. Spontaneous closure of the sinus tract should be expected within 5 to 14 days after completing the root canal treatment or the extraction (4).

## CONCLUSION

The diagnosis of a cutaneous sinus tract is not an easy task due to the absence of symptoms and the distance between origin and lesion. A dental cause must always be considered in the differential diagnosis. A proper examination and diagnosis of the underlying dental cause can avoid unnecessary antibiotic and surgical therapies. CBCT can be of use in the diagnosis and follow up of these lesions. The patient in this case was successfully treated with non-surgical endodontic therapy and a supplemental antibiotic regime.



**Video 1.** Clinical appearance of the extraoral granuloma (00:00-00:48), exploration of the sinus tract with a gutta percha cone (00:49-00:58), clinical appearance of the scar tissue after treatment (00:59-01:30)

**Informed Consent:** N/A.

**Peer-review:** Externally peer-reviewed.

**Author contributions:** Concept - F.C., P.L.; Design - F.C., P.L., P.D.H.; Supervision - F.C., P.L.; Data Collection and/or Processing - F.C.; Analysis and/or Interpretation - F.C., P.L., P.D.H.; Literature Search - F.C.; Writing - F.C.; Critical Reviews - F.C., P.L., P.D.H.

**Conflict of Interest:** No conflict of interest was declared by the authors.

**Financial Disclosure:** The authors declared that this study has received no financial support.

## REFERENCES

- Abbott PV. Classification, diagnosis and clinical manifestations of apical periodontitis. *Endod Topics* 2004; 8(1):36-54. [\[CrossRef\]](#)
- Ricucci D, Siqueira JF Jr. *Endodontology. An integrated biological and clinical view.* 1<sup>st</sup> ed. London: Quintessence Pub. Co; 2013. p. 210-4.
- Gupta M, Das D, Kapur R, Sibal N. A clinical predicament - diagnosis and differential diagnosis of cutaneous facial sinus tracts of dental origin: a series of case reports. *Oral Surg Oral Med Oral Path Oral Radiol Endod* 2011; 112(6):132-6. [\[CrossRef\]](#)
- Johnson BR, Remeikis NA, Vancura JE. Diagnosis and treatment of cutaneous facial sinus tracts of dental origin. *J Am Dent Assoc* 1999; 130(6):832-6. [\[CrossRef\]](#)
- Mittal N, Gupta P. Management of extra oral sinus cases: A clinical dilemma. *J Endod* 2004; 30(7):541-6. [\[CrossRef\]](#)
- Tidwell E, Jenkins JD, Ellis CD, Hutson B, Cederberg RA. Cutaneous odontogenic sinus tract to the chin: a case report. *Int Endod J* 1997; 30(5):352-5. [\[CrossRef\]](#)
- European Society of Endodontology. Quality guidelines for endodontic treatment: consensus report of the European Society of Endodontology. *Int Endod J* 2006; 39(12):921-30. [\[CrossRef\]](#)
- Cantatore JL, Klein PA, Liebllich LM. Cutaneous dental sinus tract, a common misdiagnosis: a case report and review of the literature. *Cutis* 2002; 70(5):264-7.
- Patterson JW. *Weedon's Skin Pathology.* 4<sup>th</sup> ed. London: Churchill Livingstone Elsevier; 2010.
- American Association of Endodontics. Antibiotics and the treatment of endodontic infections. *AAE Endodontics Colleagues for Excellence* 2006; 1-6.
- Ricucci D, Siqueira JF Jr. Apical actinomycosis as a continuum of intraradicular and extraradicular infection: case report and critical review on its involvement with treatment failure. *J Endod* 2008; 34(9):1124-9 [\[CrossRef\]](#)
- Baumgartner JC, Hutter JW, Siqueira JF Jr. Endodontic microbiology and treatment of infections. In: Cohen S, Hargreaves KM, eds. *Pathways of the pulp*, 9<sup>th</sup> ed. St. Louis: Mosby/Elsevier; 2006: 580-607.
- Rôças IN, Siqueira JF Jr, Andrade AFB, Uzeda M. Identification of selected putative oral pathogens in primary root canal infections associated with symptoms. *Anaerobe* 2002; 8(4):200-8. [\[CrossRef\]](#)
- Jacinto RC, Gomes BP, Shah HN, Ferraz CC, Zaia AA, Souza-Filho FJ. Incidence and antimicrobial susceptibility of porphyromonas gingivalis isolated from mixed endodontic infections. *Int Endod J* 2006; 39(1):62-70. [\[CrossRef\]](#)
- Tronstad L, Barnett F, Riso K, Slots J. Extraradicular endodontic infections. *Endod Dent Traumatol* 1987; 3(2):86-90. [\[CrossRef\]](#)
- Soriano de Souza CA, Teles RP, Souto R, Chaves MEA, Colombo APV. Endodontic therapy associated with calcium hydroxide as an intracanal dressing: microbiologic evaluation by the checkerboard DNA-DNA hybridization technique. *J Endod* 2005; 31(2):79-83. [\[CrossRef\]](#)
- Lansdown AB, Mirastschijski U, Stubbs N, Scanlon E, Agren MS. Zinc in wound healing: theoretical, experimental, and clinical aspects. *Wound Repair Regen* 2007; 15(1):2-16. [\[CrossRef\]](#)
- Danby SG, Chittock J, Brown K, Albenali LH, Cork MJ. The effect of tacrolimus compared with betamethasone valerate on the skin barrier in volunteers with quiescent atopic dermatitis. *Br J Dermatol* 2014; 170(4):914-21. [\[CrossRef\]](#)
- Guevara-Gutiérrez E, Riera-Leal L, Gómez-Martínez M, Amezcua-Rosas G, Chavez-Vaca CL, Tlacuilo-Parra A. Odontogenic cutaneous fistulas: clinical and epidemiologic characteristics of 75 cases. *Int J Dermatol* 2015; 54(1):50-5. [\[CrossRef\]](#)
- Kaban LB. Draining skin lesions of dental origin: the path of spread of chronic odontogenic infection. *Plast Reconstr Surg* 1980; 66(5):711-7. [\[CrossRef\]](#)
- Patel N, Shetty R, Katkade A, Agrawalla A, Somani S, Jagtap P. Non-surgical endodontic management of extra-oral cutaneous sinus tract: a case report. *Int J Sci Stud* 2015; 2: 196-9.
- Abuabara A, Schramm CA, Zielak JC, Baratto-Filho F. Dental infection simulating skin lesion. *An Bras Dermatol* 2012; 87(4):619-21. [\[CrossRef\]](#)
- Tian J, Liang G, Qi W, Jiang H. Odontogenic cutaneous sinus tract associated with a mandibular second molar having a rare distolingual root: a case report. *Head Face Med* 2015; 11: 13. [\[CrossRef\]](#)
- Cohença N, Karni S, Rotstein I. Extra oral sinus tract misdiagnosed as an endodontic lesion. *J Endod* 2003; 29(12):841-3. [\[CrossRef\]](#)
- Bai J, Ji AP, Huang MW. Submental cutaneous sinus tract of mandibular second molar origin. *Int Endod J* 2014; 47(12):1185-91. [\[CrossRef\]](#)
- Pasternak-Junior B, Teixeira CS, Silva-Sousa YT, Sousa-Neto MD. Diagnosis and treatment of odontogenic cutaneous sinus tracts of endodontic origin: three case studies. *Int Endod J* 2009; 42(3):271-6. [\[CrossRef\]](#)
- Bodner L, Manor E, Joshua BZ. Cutaneous sinus tract of dental origin in children - a report of 28 new cases. *Pediatr Dermatol* 2012; 29(4):421-5. [\[CrossRef\]](#)